Downloaded from http://bjo.bmj.com/ on April 4, 2018 - Published by group.bmj.com
BJO Online First, published on March 29, 2018 as 10.1136/bjophthalmol-2017-311471

Acute retinal toxicity associated with a mixture of perfluorooctane and perfluorohexyloctane: failure of another indirect cytotoxicity analysis

Rosa M Coco,[1,2] Girish K Srivastava,[1,3] Cristina Andrés-Iglesias,[4,5] Jesús Medina,[4] Fernando Rull,[4] Alvaro Fernandez-Vega-Gonzalez,[6] Ivan Fernandez-Bueno,[1,2,3] Antonio Dueñas,[1,7] Jose C Pastor[1,2,8]

► Additional material is published online only. To view please visit the journal online (http://dx.doi.org/10.1136/bjophthalmol-2017-311471).

[1]Instituto Universitario de Oftalmobiología Aplicada (IOBA), Eye Institute, University of Valladolid, Valladolid, Spain
[2]Red Temática de Investigacion Cooperativa en Salud de Oftalmologia (Oftared), Instituto de Salud Carlos III, Madrid, Spain
[3]Centro en Red de Medicina Regenerativa y Terapia Celular, Junta de Castilla y Leon, Valladolid, Spain
[4]Departament of Physics of Condensed Matter, Crystallography and Mineralogy, University of Valladolid, Valladolid, Spain
[5]High Pressure Processes Group, Department of Chemical Engineering and Environmental Technology, University of Valladolid, Valladolid, Spain
[6]Instituto Oftalmologico Fernandez-Vega, Oviedo, Spain
[7]Toxicology Department, University of Valladolid, Valladolid, Spain
[8]Department of Ophthalmology, Hospital Clinico Universitario of Valladolid, Valladolid, Spain

Correspondence to
Dr Girish K Srivastava, Instituto Universitario de Oftalmobiología Aplicada (IOBA), Eye Institute, University of Valladolid, Valladolid 47011, Spain; girish@ioba.med.uva.es

Received 23 October 2017
Revised 21 February 2018
Accepted 28 February 2018

Check for updates

To cite: Coco RM, Srivastava GK, Andrés-Iglesias C, *et al*. *Br J Ophthalmol* Epub ahead of print: [*please include* Day Month Year]. doi:10.1136/bjophthalmol-2017-311471

ABSTRACT

Aims To report new information related to acute retinal toxicity of Bio Octane Plus, a mixture of 90% perfluorooctane (PFO) and 10% perfluorohexyloctane.

Methods This retrospective, descriptive case series reports the occurrence of acute retinal toxicity after vitreoretinal surgery in which Bio Octane Plus (batch number 1605148) was used as an endotamponade. Cytotoxicity biocompatibility tests and chemical analyses by Fourier-transformed infrared (FTIR) spectroscopy and gas chromatography-mass spectrometry (GC-MS) of the presumed toxic product were performed.

Results Four patients presented with acute severe visual loss after uneventful ocular surgery assisted by Bio Octane Plus (batch number 1605148) as endotamponade. Patients experienced extensive retinal vascular occlusion leading to retinal and optic nerve atrophy. The viability of ARPE-19 cells directly exposed to the suspect batch for 30 min was 0%. The agarose overlay method used by the manufacturer according to European Union regulations and International Organization for Standardization (ISO) International Standards failed to detect toxicity. FTIR spectroscopy showed small differences between the non-toxic and toxic batches. GC-MS analysis showed the presence of bromotributyl stannane (whose toxicity was demonstrated in the dose–response curve) only in the toxic batch of Bio Octane Plus.

Conclusion This is the third report of retinotoxicity due to PFO in 4 years. The clinical profiles may be missed as they resemble other postsurgical complications; therefore, more cases worldwide could have gone unreported. Protocols to determine cytotoxicity of intraocular medical devices and approved by the ISO International Standards based on indirect methods have failed and should be revised to ensure safety.

INTRODUCTION

Physicochemical properties of perfluorocarbon liquids (PFCLs) make them useful tools in vitreoretinal surgery,[1] but they tend to induce inflammation, limiting their use as a long-term tamponade. However, they are routinely and safely used intraoperatively for manipulation of the retina. Particularly useful is perfluorooctane (PFO), which has the advantages of low viscosity, easily visible interface, relatively high vapour pressure and availability as a highly purified compound.[2] Perfluorohexyloctane (F6H8) is a semifluorinated alkane used as a long-term tamponade alone[3 4] or combined with silicone oil (SiO)[5] providing good support to the inferior retina due to its specific gravity.[6] There are no papers on the safety and efficacy of the combination of PFCL and F6H8, except one, in rabbits, demonstrating lack of association between F6H8 specific gravity and retinal degeneration after long-term tamponade.[7]

Recently, several PFO toxicity episodes producing irreversible vision loss have occurred.[8–11] Related toxic products fulfilled all of the requirements to obtain the CE mark having been tested by independent certified companies using tests according to the International Organization for Standardization (ISO) accepted in Europe and worldwide. In 2013, Meroctane (Meran, Istanbul, Turkey) affected seven patients reported to Chile's Health Authorities and four cases to the Spanish Agency for Drugs and Medical Devices. There are no scientific papers documenting those cases, and cause was not elucidated. Then, over a hundred of Spanish patients and others along Europe suffered retinal toxicity associated with AlaOcta (AlaMedics, Dornstadt, Germany).[8–11] Cytotoxicity testing by extract dilution method, performed by an independent company, failed to detect this toxicity.[8 9]

The purpose of this paper is to report clinical and experimental information of a new episode of retinal toxicity associated with the use of Bio Octane Plus (Biotech Vision Care, Gujarat, India). This product, composed of 90% PFO and 10% F6H8, was tested under the ISO 10993 protocols using an agarose overlay method, which failed to detect toxicity. This information is critical to update the EN-ISO guidelines for evaluating the safety of intraocular surgical tools, EN-ISO 16672 Ophthalmic implants-Ocular endotamponades and EN-ISO 10993 Biological evaluation of medical devices.

MATERIALS AND METHODS

Patient examinations

Retrospective, descriptive case series study. Information was peer-evaluated by experts from the Spanish Vitreo-Retina Society according to previously described clinical signs of PFO toxicity after the AlaOcta episode.[9–11]

Copyright Article author (or their employer) 2018. Produced by BMJ Publishing Group Ltd under licence.

Downloaded from http://bjo.bmj.com/ on April 4, 2018 - Published by group.bmj.com

Cytotoxicity tests

Cytotoxicity tests were performed in a UNE-EN-ISO 9001 and Good Laboratory Practice-certified laboratory at the Instituto Universitario de Oftalmobiología Aplicada, University of Valladolid, Valladolid, Spain.

Direct contact method

This previously described method is based on the direct contact of cells with the item, incorporating important technical steps (Spanish patent no. 201630708 and International PCT no. ES2017/070365). In brief, suspected product to cause clinical toxicity, Bio Octane Plus (batch number 1605148) was tested by placing it in direct contact with human retinal pigment epithelial cells (ARPE-19 cells, American Tissue Culture Collection, Rockville, Maryland, USA) for 30 and 60 min, and then they were grown for 24 and 72 hours. Cytotoxicity was evaluated by performing the 3-(4,5-dimethylthiazol-2-yl)−2,5-diphenyltetrazolium bromide assay (MTT; Sigma-Aldrich, St. Louis, Missouri, USA). Blank cultures were maintained without any treatment. A positive control was exposed to liquefied phenol (Sigma-Aldrich) meeting United States Pharmacopeia testing specifications. Negative controls were exposed to Bio Octane Plus (batch number 1406119), which was thought to be non-toxic as it had no history of ocular complications, and to two other PFOs from two separate manufacturers (not disclosed). Following the UNE-EN-ISO 10993 (Part 5: Tests for in vitro cytotoxicity), cytotoxicity was established if cell viability was reduced to $\leq$70%.[8 9]

Agarose overlay method

The agarose overlay method was partially reproduced in our lab. A 2 mL mixture of agarose and culture medium was poured to solidify in a well of a six-well culture plate and the height above each well bottom was measured. Then filter papers covering approximately one-tenth of the well diameter were saturated with test samples and quickly transferred to the solidified agarose surface.

Structural and chemical analysis

Suspected toxic sample (batch number 1605148) and control (batch number 1406119) were structural and chemical analysed by Fourier-transformed infrared (FTIR) spectroscopy in transmission mode and with attenuated total reflectance. They were also analysed in triplicate by gas chromatography (GC, 7890B, Agilent Technologies, Santa Clara, California, USA) equipped with a quadrupole mass spectrometer (MS, 5977A, Agilent Technologies). Chromatographic separation data were acquired using a HP5-ms 30 m × 0.25 mm × 0.25 µm capillary column (Agilent Technologies). Analyses were performed in the split (1:200) and non-split modes.

Dose–response curve

The chemical analysis showed the presence of bromotributyl stannane whose amount was calculated by a calibration curve (R^2=0.996) with control PFO as solvent and the bromotributyl stannane standard at different concentrations. A dose–response curve of suspected toxic agent bromotributyl stannane on ARPE-19 cell culture was performed. Cells were exposed for 30 min with the toxic agent and then grown for 24 hours, followed by cell cytotoxicity measurement using MTT assay.

RESULTS

Patient examinations

Four consecutive patients underwent uneventful vitreoretinal surgery by two experienced surgeons from the same clinic using Bio Octane Plus, batch number 1605148. Each patient presented features compatible with severe acute retinal toxicity. None of the patients presented postoperative intraocular pressure increase the following days that could justify the final optic atrophy observed (see online supplementary table 1) neither present postoperative pain.

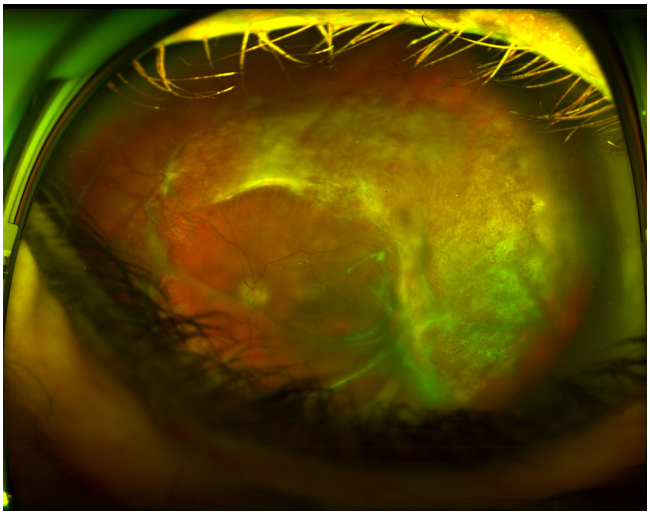

Figure 1 Postoperative fundus retinography of case 1 showing retinal detachment and proliferative vitreoretinopathy in the peripheral retina and at the posterior pole.

Case 1

A 78-year-old patient presented with a luxated intraocular lens (IOL) that was refloated. The next day, visual acuity (VA) was only light perception (LP) in the operated eye. Ocular fundus (OF) was cloudy as the anterior segment was moderately inflamed (see online supplementary figure 1). Few days later, signs of vascular closure and retinal necrosis were observed (see online supplementary figure 2). Fluorescein angiography revealed a massive retinal vascular occlusion in early frames and staining of the necrotic temporal area in late frames (see online supplementary figure 3). Several weeks later the patient presented with retinal detachment (RD) that complicated with proliferative vitreoretinopathy and optic nerve atrophy (ONA) (figure 1). Optical coherence tomography (OCT) showed first foveal disruption with a subfoveal deposit (see online supplementary figure 4 and supplementary video V1) followed by generalised decreased retinal thickness (see online supplementary video V2) .

Case 2

A high myopic 48-year-old patient, who had previously undergone cataract surgery and reattachment of an RD, presented with IOL luxation that needed surgical repair. The day after surgery, VA was no LP. Severe postoperative inflammation and extensive vascular occlusion were present on OF. Three days later, the RD relapsed, requiring reintervention. ONA developed later.

Case 3

A 57-year-old patient with moderate myopia presented with a large retinal tear and RD. VA was LP on the day after surgery. When gas disappeared, extensive retinal vascular ischaemia, filiform vessels, areas of retinal necrosis and yellow exudates were observed on OF (figure 2). The applied retina was very thin on OCT with foveal atrophy (see online supplementary figure 5 and

Downloaded from http://bjo.bmj.com/ on April 4, 2018 - Published by group.bmj.com

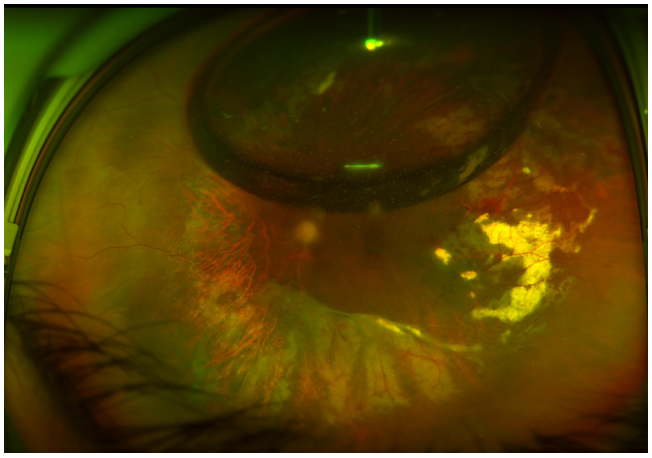

Figure 2 Postoperative retinography of case 3; the applied retina was atrophic with severe exudation.

supplementary video V3). Thereafter RD relapsed (see online supplementary figure 5 and supplementary video V4) .

Case 4

A 63-year-old patient presented with no LP the day after RD surgery. A massive retinal vascular occlusion was present, followed by ONA (figure 3) and foveal atrophy on OCT (see online Supplementary figure 6 and supplementary video V5).

Cytotoxicity tests

Contact method

Cell cultures were evaluated by phase contrast optical microscopy (see online supplementary figure 7). Cell cultures of blank and negative control groups were confluent. In contrast, cells exposed to liquid phenol, positive control, were not confluent. Cells that were in contact with the suspected toxic item (batch number 1605148) were also not confluent. The viability of these confluent and non-confluent cell layers was measured using the MTT assay (figure 4). The results showed that the mean optical density was ≥0.2 in the blank group, and the difference of percentage viabilities for the right and left blank groups were ≤15% from an average of the sum of both, thus achieving ISO protocol standards. Cultures exposed to the positive control, liquefied phenol, showed a 0% viability in each condition (≤70% and therefore toxic according to ISO standards). Viabilities of cultures exposed to each negative control (batch number 1406119) and the two PFOs from other manufacturers (MF1 and MF2) were between 110% and 97% when exposed for 60 min and cultured another 72 hours (≥70% and therefore non-toxic according to the ISO standards). On exposure for 30 min and followed by 72-hour cell growth, the two PFOs (MF1 and MF2) had between 102% and 96% viability, respectively (≥70%; non-toxic according to the ISO standards). In contrast, cultures exposed to batch number 1605148 had 0% viability in all experimental conditions, confirming its toxicity.

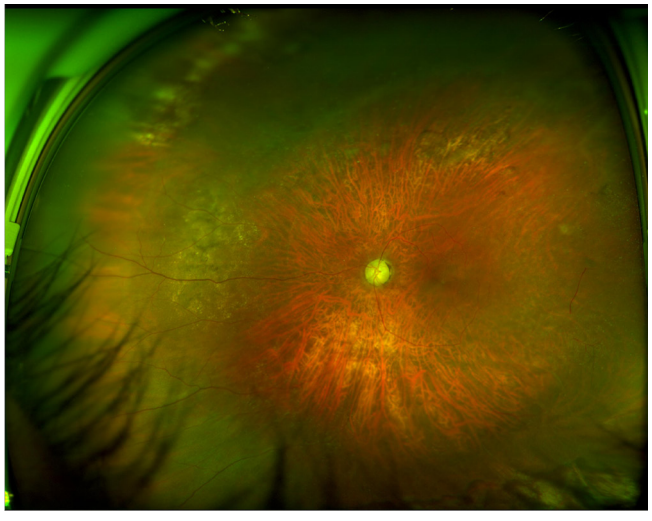

Figure 3 Postoperative retinography of case 4 showing retinal ischaemia, optic atrophy and a very atrophic retina.

Agarose overlay method

The 2 mL agarose solution made a layer 2.5 mm above bottom of culture plate where cells can be grown. This layer prevented direct contact between test samples and cells because PFO, immiscible with water, was unlikely to diffuse across the agarose layer. Filter paper did not absorb the PFO as it does for phosphate-buffered saline; therefore, we had serious concerns regarding exact PFO quantity absorbed. Additionally, due to the high volatility of the PFO and the small volume placed on each filter paper, it is likely that none or only a very small (and unknowable) amount of test substance could have reached the bottom. These initial and critical observations revealed the weakness of this method, and we discarded further investigations with it.

Structural and chemical analysis

FTIR spectroscopy showed that PFO and F6H8 in the non-toxic and toxic batches were similar, and no alterations in these components that could account for the toxicity were identified. Therefore, we concluded that a different molecule must be present in the toxic batch.

GC-MS analysis showed two similar clear peaks of PFO and F6H8 in both non-toxic and toxic batches (figure 5A). However, a different peak was identified in the toxic compared with the control (figure 5B). This peak corresponded to bromotributyl stannane, also called tributyltin bromide (retention time, 41.637 min, $C_{12}H_{27}BrSn$, 369.975 Da), according to the mass spectra database of the GC-MS (Wiley library; http://www.sisweb.com/software/ms/wiley.htm). The reference ions (*m*/*z*) of the spectra were 313.0, 198.8, 57.1, 256.9, 177.0, 41.1 and 120.9.

Dose–response curve

The amount of bromotributyl stannane in the toxic PFO sample was 0.23 mg/mL.

The dose–response curve of this suspected toxic agent bromotributyl stannane confirmed its human retinal toxicity at the levels found in the toxic PFO as 100% mortality of cells was found over 0.039 mg/mL (see online supplementary figure 8).

DISCUSSION

Four major clinical profiles of retinal toxicity after uneventful surgery are (1) very low VA the day after, (2) ONA, (3) acute retinal necrosis and (4) retinal arterial and/or venous occlusion, which sometimes result in severe vitreoretinal proliferation.[9 11] Severe early postoperative inflammation and/or late *rubeosis iridis* can also occur.[9 11] Experienced surgeons may miss these symptoms as they resemble some infrequent but not exceptional complications. That may explain why retinal toxicity could be difficult to identify, and ophthalmologists must be aware of the

Downloaded from http://bjo.bmj.com/ on April 4, 2018 - Published by group.bmj.com

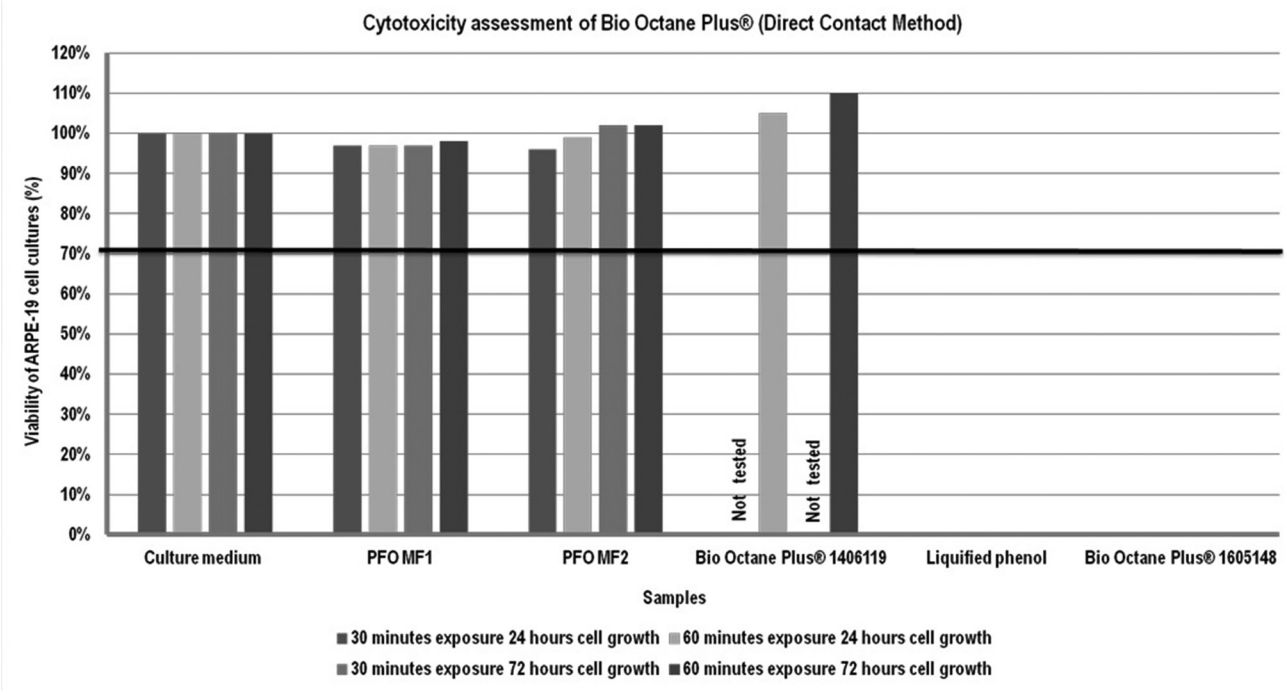

Figure 4 Cytotoxicity assessment of Bio Octane Plus (batch numbers 1605148 and 1406119) on retinal pigment epithelial cells (ARPE-19 cell line). The ARPE-19 cell cultures were prepared and directly exposed for 30 and 60 min to various negative controls: culture medium, perfluorooctane (PFO) samples of manufacturers 1 and 2 (MF1, MF2, tested repeatedly (n≥3), non-cytotoxic) and Bio Octane Plus batch number 1406119 (suspected to be non-cytotoxic; batch number 1406119 was tested for only 60 min and cultured for 24 and 72 hours due to the scarce amount of sample available). The positive control consisted of liquefied phenol. The suspected toxic product was Bio Octane Plus batch number 1605148. After the exposure period, the cell cultures are grown for the next 24 or 72 hours, and the 3-(4,5-dimethylthiazol-2-yl)−2,5-diphenyltetrazolium bromide assay was performed to detect cell culture viability. The results were compared by setting the mean optical density of the control culture medium group to 100%. The results confirmed that culture viability was >70% for all negative groups including Bio Octane Plus batch number 1406119 (non-cytotoxic as per the International Organization for Standardization (ISO) 10993-5:2009 norms) and <70% for positive control group and Bio Octane Plus batch number 1605148 (cytotoxic as per ISO 10993-5:2009 norms).

possible toxic origin of such clinical findings, even in patients with a poor prognosis.

Two different cytotoxicity tests were used in this study. While the direct contact method[8] clearly detected the toxic batch, the agar overlay assay failed and had critical weaknesses as described previously. Prior to commercialisation, the two PFOs batches used in this study, number 1406119 (control) and number 1605148 (toxic), were tested by the agarose overlay method performed by Bioneeds India Private Limited (Karnataka, India) under commission by the manufacturer, as per ISO 10993-5:2009(E). Culture wells with L-929 mouse fibroblast cells were used. The growth medium in each well was replaced with 2 mL of agarose mixture. Filter paper discs covering approximately one-tenth of the well diameter were saturated with the test item, and samples were placed on the agarose layer in triplicate. Similarly, the same size filter discs saturated with 0.9% normal saline and a negative control consisting of high-density polyethylene or a positive control containing polyurethane were placed on the agarose. Cells were evaluated 24, 48 and 72 hours after incubation, and the cytotoxicity was scored. Culture cells treated with batch number 1605148 disclosed no reactivity when examined microscopically, and it was considered to be non-cytotoxic. However, this test protocol revealed weakness when repeated in our lab. Considering these limitations, it is highly likely that the tested items were not in contact with the cultured cells in sufficient concentration and/or for a sufficient amount of time to identify the cellular toxicity. By using our direct contact method, we confirmed the cytotoxicity of this batch and identified toxic compounds by FITR and GC-MS.

Toxic effects of PFCL have been known since the early 1990s, although these compounds are well tolerated for short-term use.[1 12] Toxicity was classically attributed to a combination of chemical and mechanical mechanisms. PFCLs are synthetic compounds obtained from hydrocarbons by replacing hydrogen with fluorine atoms, and the toxicity has been attributed mainly to small amounts of polar impurities.[13] Thus to decrease chemical toxicity, PFCLs should ideally be highly purified and free of CH–, double bonds and partially fluorinated products.[14] Hydrogen nuclear magnetic resonance, infrared spectroscopy and cell cultures have been used to determine the presence of these compounds,[15 16] but they are not performed routinely. The presence of the toxic polar impurities may not occur only during the synthesis process. Rather, they can appear in the final commercialised product during storage as a result of PFCL oxidation as demonstrated with AlaOcta.[9] Thus we strongly recommend the analysis of the final products before clinical use.

Histological changes increased in PFCLs with higher specific gravity and have been attributed to mechanical toxicity[1 17 18] as similar changes appeared in the superior retina after contact with SiO.[19 20] Other authors questioned the role of gravity and attributed retinal changes to the lack of contact with the scarce aqueous component of the vitreous cavity.[7] Nevertheless, those changes were subtle and very different from the dramatic damage suffered by our patients in which batch number 1605148 was used.

Downloaded from http://bjo.bmj.com/ on April 4, 2018 - Published by group.bmj.com

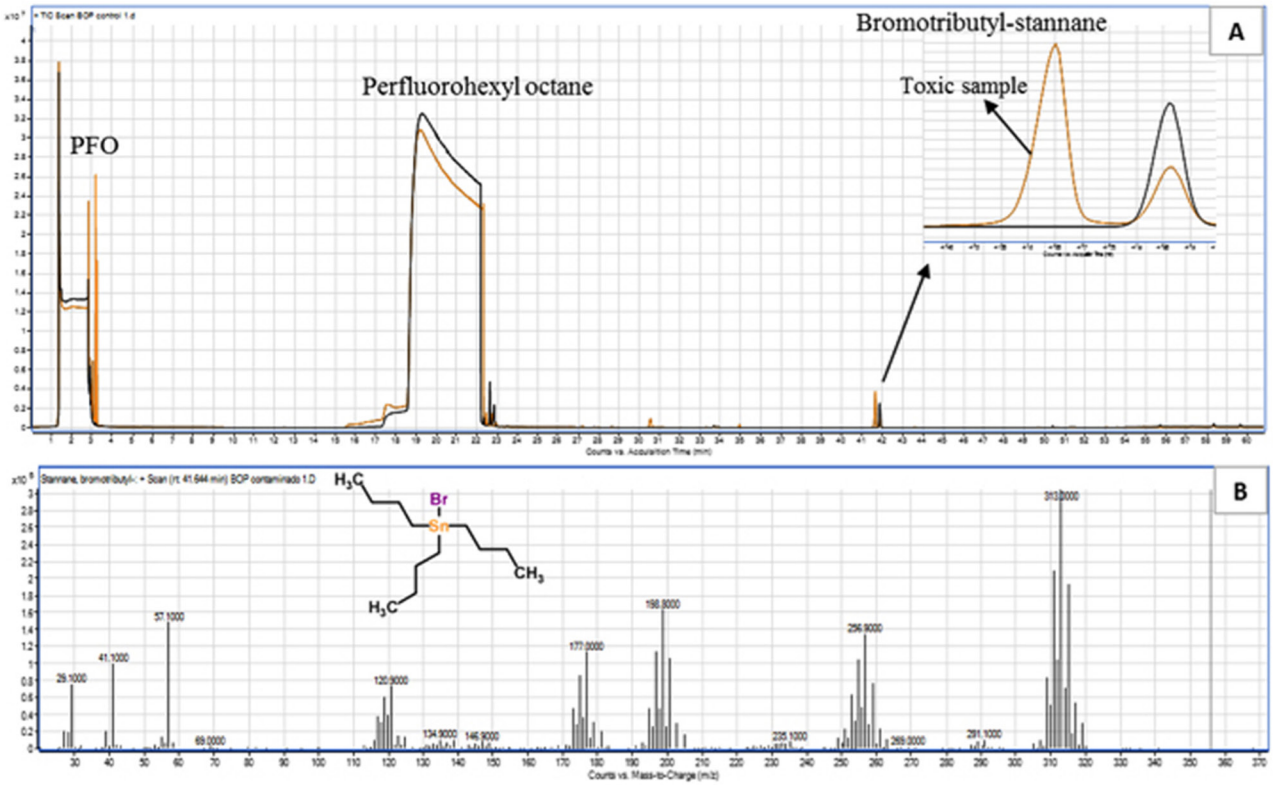

Figure 5 Gas chromatography-mass spectrometry analysis of non-cytotoxic Bio Octane Plus batch number 1406119 and cytotoxic Bio Octane Plus batch number 1605148. (A) Chromatogram of the control perfluorooctane (PFO) Bio Octane Plus batch number 1406119 (black) and the toxic Bio Octane Plus batch number 1605148 (orange); (B) bromotributyl stannane (tributyltin bromide) spectra.

According to the manufacturer, the inclusion of F6H8 reduces the specific gravity compared with pure PFO, provides ideal interfacial and surface tension to prevent subretinal penetration, and has laser stability and poor solubility in SiO. Nevertheless, we have been unable to find any scientific report on the ophthalmic use of that mixture. F6H8 represents a groundbreaking water-free resource for treatment of evaporative dry eye disease,[21] but it is mainly used as a long-term internal tamponade.[3 5] It is well tolerated for a few weeks, but when left longer in the eye, adverse side effects emerge.[4 22 23] F6H8 decreased cell viability in cultures more than did perfluorodecalin and the loss of viability could not be attributed solely to mechanical effects or nutritional deficits because F6H8 has a lower specific gravity. Thus, the high lipophilicity of F6H8 and its interactions with cellular lipoprotein membranes or other toxic effects may play a role in its toxicity.[24]

In the case of AlaOcta, two hydroxyl compounds and benzene derivatives were the identified toxic agents.[9] In the present case, GC-MS analysis showed the presence of the toxic bromotributyl stannane, an organotin compound also known as tributyltin bromide, bromotributyltin, tri-*n*-butyltin bromide and tri-*n*-butylbromotin (CAS registry number 1461-23-0). This substance is used for agricultural, industrial and biomedical applications. Systemic toxicity of organotin compounds or stannanes is well known,[25] including effects on the retinal neurons of developing zebrafish[26]; however, there have been no data on human retinal toxicity until now. Besides our dose–response curve confirmed its human retinal toxicity at the levels found in the toxic batch of Bio Octane Plus. Additionally, we found other differential compounds when the samples were analysed in split mode (1:200), and these could also be PFO derivatives, such as perfluorohexane, with different chain lengths. More chemical research is needed to clarify the origin(s) of the toxic contaminants. Cooperation of supplier companies will be necessary for this effort.

In summary, we have reported for the first time a new, dramatic episode of acute ocular toxicity related to the use of a surgical tool made with PFO and F6H8. These findings represent another failure of indirect cytotoxicity analysis performed under ISO guidelines as required for commercialisation of products in the European Union (EU). This report, along with already reported cases involving AlaOcta, emphasises the necessity to update the EU and ISO guidelines for biological evaluation of ophthalmic devices (ISO 16672 and ISO 10993) according to the current safety needs of the market. Efforts should be made to clarify when and how these final commercial products gained toxicity between the manufacturers and the end users so that similar problems can be avoided in future. This information should be shared among companies, ophthalmologists and all health authorities.

Acknowledgements Spanish Agency of Medicines and Medical Devices (AEMPS) from the Spanish Ministry of Health and SERV (Spanish Vitreo Retina Society). M Teresa Gutierrez contributed supporting the acquisition of data on cytotoxicity tests.

Contributors RMC wrote the paper and contributed to drafting the work for important intellectual content. GKS and IF-B contributed to the conception and design of the work, the analysis and interpretation of cytotoxicity test data. JM, CA-I and FR contributed to the conception and design of the work, the acquisition, analysis or interpretation of data on structural and chemical tests. AFV-G contributed to the write clinical data. AD identified the toxicity of the chemical compounds. JCP and FR contributed to drafting the work for important intellectual content. All authors are responsible for the final approval of the version to be published and agree to be accountable for all aspects of the work in ensuring that questions

Downloaded from http://bjo.bmj.com/ on April 4, 2018 - Published by group.bmj.com

related to the accuracy or integrity of any part of the work are appropriately investigated and resolved.

Funding This research received no specific grant from any funding agency in the public, commercial or not-for-profit sectors.

Competing interests None declared.

Patient consent Not required.

Provenance and peer review Not commissioned; externally peer reviewed.

© Article author(s) (or their employer(s) unless otherwise stated in the text of the article) 2018. All rights reserved. No commercial use is permitted unless otherwise expressly granted.

REFERENCES

1 Chang S, Zimmerman NJ, Iwamoto T, *et al*. Experimental vitreous replacement with perfluorotributylamine. *Am J Ophthalmol* 1987;103:29–37.
2 Coll GE, Chang S, Sun J, *et al*. Perfluorocarbon liquid in the management of retinal detachment with proliferative vitreoretinopathy. *Ophthalmology* 1995;102:630–9.
3 Tosi GM, Marigliani D, Bacci T, *et al*. F6H8 as an Intraoperative Tool and F6H8/Silicone Oil as a Postoperative Tamponade in Inferior Retinal Detachment with Inferior PVR. *J Ophthalmol* 2014;2014:1–9.
4 Schatz B, El-Shabrawi Y, Haas A, *et al*. Adverse side effects with perfluorohexyloctane as a long-term tamponade agent in complicated vitreoretinal surgery. *Retina* 2004;24:567–73.
5 Wong D, Van Meurs JC, Stappler T, *et al*. A pilot study on the use of a perfluorohexyloctane/silicone oil solution as a heavier than water internal tamponade agent. *Br J Ophthalmol* 2005;89:662–5.
6 Kirchhof B, Wong D, Van Meurs J, *et al*. Use of perfluorohexyloctane as a long-term internal tamponade agent in complicated retinal detachment surgery. *Am J Ophthalmol* 2002;133:95–101.
7 Mackiewicz J, Maaijwee K, Lüke C, *et al*. Effect of gravity in long-term vitreous tamponade: in vivo investigation using perfluorocarbon liquids and semi-fluorinated alkanes. *Graefes Arch Clin Exp Ophthalmol* 2007;245:665–75.
8 Srivastava GK, Alonso-Alonso ML, Fernandez-Bueno I, *et al*. Comparison between direct contact and extract exposure methods for PFO cytotoxicity evaluation. *Sci Rep* 2018;8:1425.
9 Pastor JC, Coco RM, Fernandez-Bueno I, *et al*. Acute retinal damage after using a toxic perfluoro-octane for vitreo-retinal surgery. *Retina* 2017;37:1140–51.
10 Pastor Jimeno JC, Coco Martin RM. El problema de la toxicidad aguda de algunos perfluoro-octanos. *Archivos de la Sociedad Española de Oftalmología* 2017;92:455–7.
11 Méndez-Martínez S, Calvo P, Rodriguez-Marco NA, *et al*. Blindness related to presumed retinal toxicity after using perfluorocarbon liquid during vitreoretinal surgery. *Retina* 2017;18:1.
12 Drury B, Bourke RD. Short-term intraocular tamponade with perfluorocarbon heavy liquid. *Br J Ophthalmol* 2011;95:694–8.
13 Sparrow JR, Ortiz R, MacLeish PR, *et al*. Fibroblast behavior at aqueous interfaces with perfluorocarbon, silicone, and fluorosilicone liquids. *Invest Ophthalmol Vis Sci* 1990;31:638–46.
14 Velikay M, Stolba U, Wedrich A, *et al*. The effect of chemical stability and purification of perfluorocarbon liquids in experimental extended-term vitreous substitution. *Graefes Arch Clin Exp Ophthalmol* 1995;233:26–30.
15 Falco L, Utari S. Esente S: Comparison of different perfluorocarbon liquids. *J Vitreo Retina* 1992;1:17–19.
16 Peyman GA, Schulman JA, Sullivan B. Perfluorocarbon liquids in ophthalmology. *Surv Ophthalmol* 1995;39:375–95.
17 Stolba U, Krepler K, Velikay-Parel M, *et al*. The effect of specific gravity of perfluorocarbon liquid on the retina after experimental vitreous substitution. *Graefes Arch Clin Exp Ophthalmol* 2004;242:931–6.
18 Osterholz J, Winter M, Winkler J, *et al*. [Retinal damage by perfluorocarbon liquids - a question of specific gravity? Intraocular pressure peaks and shearing forces]. *Klin Monbl Augenheilkd* 2009;226:38–47.
19 Chang S, Sparrow JR, Iwamoto T, *et al*. Experimental studies of tolerance to intravitreal perfluoro-n-octane liquid. *Retina* 1991;11:367–74.
20 Gonvers M, Hornung JP, de Courten C. The effect of liquid silicone on the rabbit retina. Histologic and ultrastructural study. *Arch Ophthalmol* 1986;104:1057–62.
21 Steven P, Scherer D, Krösser S, *et al*. Semifluorinated Alkane Eye Drops for Treatment of Dry Eye Disease--A Prospective, Multicenter Noninterventional Study. *J Ocul Pharmacol Ther* 2015;31:498–503.
22 Vote B, Wheen L, Cluroe A, *et al*. Further evidence for proinflammatory nature of perfluorohexyloctane in the eye. *Clin Exp Ophthalmol* 2003;31:408–14.
23 Malchiodi-Albedi F, Matteucci A, Formisano G, *et al*. Perfluorohexyloctane (F6H8) induces structural modifications and increases apoptosis in rat primary retinal cultures. *J Biomed Mater Res B Appl Biomater* 2003;65:133–6.
24 Mertens S, Bednarz J, Engelmann K. Evidence of toxic side effects of perfluorohexyloctane after vitreoretinal surgery as well as in previously established in vitro models with ocular cell types. *Graefes Arch Clin Exp Ophthalmol* 2002;240:989–95.
25 Nath M. Toxicity and the cardiovascular activity of organotin compounds: a review. *Appl Organomet Chem* 2008;22:598–612.
26 Dong W, Muramoto W, Nagai Y, *et al*. Retinal neuronal cell is a toxicological target of tributyltin in developing zebrafish. *J Vet Med Sci* 2006;68:573–9.

Downloaded from http://bjo.bmj.com/ on April 4, 2018 - Published by group.bmj.com

Acute retinal toxicity associated with a mixture of perfluorooctane and perfluorohexyloctane: failure of another indirect cytotoxicity analysis

Rosa M Coco, Girish K Srivastava, Cristina Andrés-Iglesias, Jesús Medina, Fernando Rull, Alvaro Fernandez-Vega-Gonzalez, Ivan Fernandez-Bueno, Antonio Dueñas and Jose C Pastor

Br J Ophthalmol published online March 29, 2018

Updated information and services can be found at:
http://bjo.bmj.com/content/early/2018/03/29/bjophthalmol-2017-311471

These include:

References This article cites 26 articles, 3 of which you can access for free at:
http://bjo.bmj.com/content/early/2018/03/29/bjophthalmol-2017-311471#ref-list-1

Email alerting service Receive free email alerts when new articles cite this article. Sign up in the box at the top right corner of the online article.

Notes

To request permissions go to:
http://group.bmj.com/group/rights-licensing/permissions

To order reprints go to:
http://journals.bmj.com/cgi/reprintform

To subscribe to BMJ go to:
http://group.bmj.com/subscribe/